

Ascaridoid nematode infection in a reticulated python

V. Gnani Charitha^{1, 5}, S. Dhilleswara Rao², Satya Prakash Arun³ and A. Prasanth Babu⁴

Abstract:

A young captive reticulated python (*Python reticulatus*) belonging to Sri Venkateswara Zoo, Tirupati, Andhra Pradesh, India died with a two weeks history of anorexia and traumatic injury. On post mortem examination, about 45-50 round worms were collected from the gut and esophageal region. Based on the external morphology of the worms and by examining the eggs, the parasite was identified as ascaridoid nematode that is commonly found parasitizing snakes in India (Ambrose *et al.* 1999 and Brar *et al.* 1990).

Introduction:

Closed environmental conditions coupled with stress of captivity predispose snakes to wide variety of endoparasites. Ascaridoid nematodes are found parasitizing in stomach, small and large intestines of snakes worldwide. Several factors influence the pathogenic effects of nematodes; they include number of parasites present, overall immune status of host, age and availability of food (Ambrose *et al.* 1999). Under poor management-conditions, overwhelming parasitism is common, the effects of which range from clinically in-apparent disease (Rao & Acharjyo, 1984) to overt clinical signs to death. In the present case, traumatic injury of python and affliction to subsequent parasitic infection might have lead to progressive deterioration of the animal's health finally leading to death.

Methodology:

A young captive reticulated python, owned by Sri Venkateswara Zoo Tirupati, was presented with two weeks history of traumatic injury at tail region (Fig.1). The animal was unable to move and due to anorexia the snake's condition continued to go down and the animal died after two weeks. On necropsy examination, large numbers of entangled worms were found firmly attached by their anterior ends into lumen of esophagus and gut (Fig.2). The worms were submitted to the Veterinary Parasitology Laboratory for parasite identification.

The recovered worms were fixed in 10% formalin. Few worms were subjected to dehydration using descending grades of ethanol (70-100%) and cleared with lacto-phenol (Meyer & Olsen 1975). Specimens were examined using compound microscopy for the morphological identification.



Fig.1. Arrow mark in the image indicates the injury at tail region of python

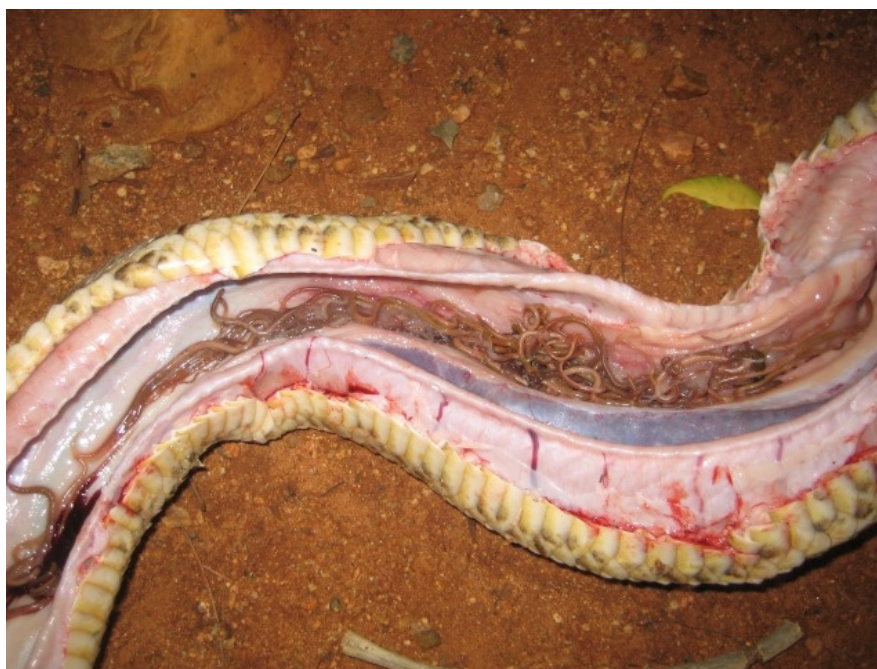

Fig.2. Image showing large number of entangled worms in the gut of python.

Result:

The nematodes ranged from 50-85mm in length, females being larger than males. Male worms were very thin and slender and females being large and stout. On microscopic examination the anterior end of the nematode consisted of well-developed interlabia and three square-shaped lips. Spicules were equal and alate. More than 30 pairs of pre-cloacal papillae, one pair of ad-cloacal and two pairs of post cloacal papillae were seen at the posterior tail end of the male. The tail end was pointed, with a conspicuous terminal mucron. The characteristic post-anal tubercle like prominence was seen at the posterior end of the worm (Fig.3).

Female worms were 60-100mm in length with three lips at the anterior end. Vulvar opening was at the anterior middle third of the body. The eggs were of typical ascarid type with thick pitted cell wall (Fig.4). Based on the morphology, the worms were identified as ascaridoid nematodes parasitizing the esophagus and stomach.

¹Department of Veterinary Parasitology,
^{2,4}Department of Veterinary Anatomy,
³Sri Venkateswara Zoo.
College of Veterinary Science,
Sri Venkateswara Veterinary University,
Andhra Pradesh
⁵ Corresponding author. E-mail:
dr.charithagnani@gmail.com

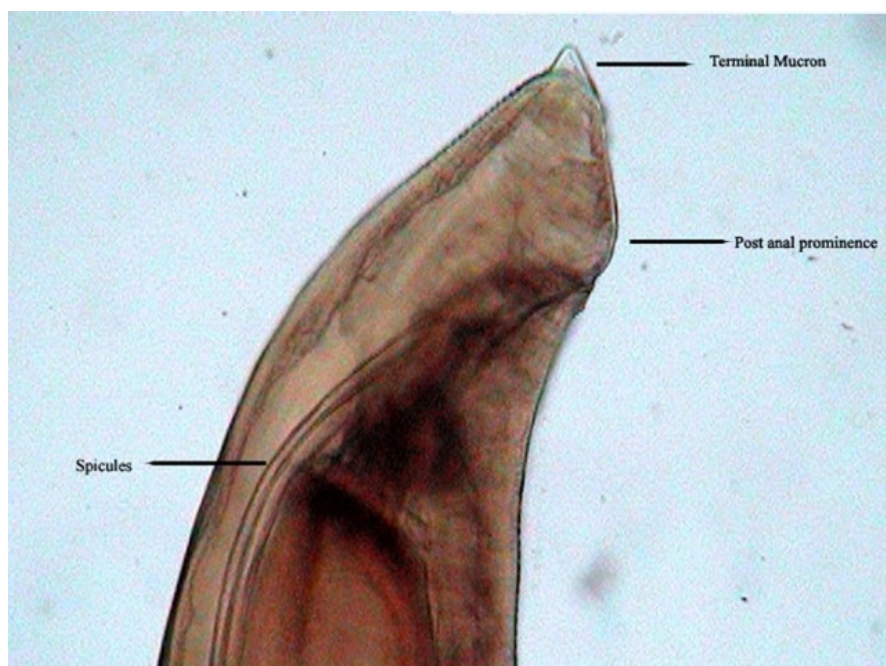


Fig.3. Photomicrograph of male tail end with characteristic terminal mucron and post anal prominence (x 100)

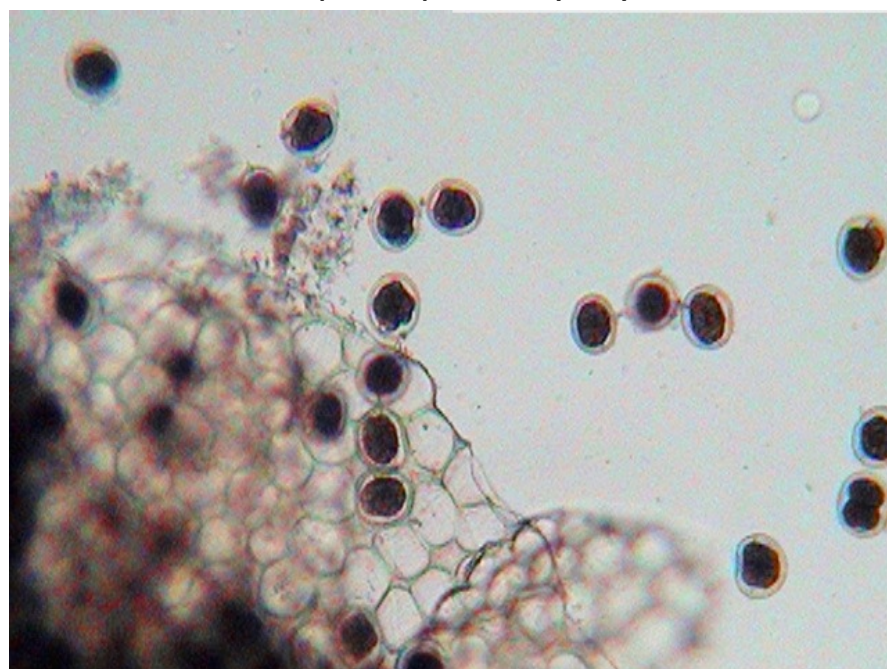


Fig.4. Note several eggs released from ruptured uterus of female worm (x 100)

Discussion: Ascaridoid nematodes have been found in pythons in Brazil and India (Panizzutti *et al.* 2003 and Brar *et al.* 1990). The known ascaridoid nematodes of snakes are *Ophidascaris* spp., *Hexametra* spp. and *Polydelphus* sp. (Burse & Brooks 2011). Many uncertainties exist regarding the taxonomic differentiation of ascaridoid nematodes because of the close morphological similarities between the genera *Ophidascaris* sp and *Hexametra* sp and between the individuals of the same genus. Generic status is merely based on number of uterine branches which may be overlooked sometimes (Siqueira *et al.* 2005). Gastrointestinal tract disturbances in pythons are associated

with large masses of worms which lead to gastric ulcerations, obstruction, poor appetite, weight loss, vomiting or regurgitation and diarrhea (Taylor *et al.* 2007). Severe complications may lead to large granulomatous masses or ulcers in GI tract leading to intestinal perforations (Ambrose *et al.* 1999).

Snake round worms have an indirect lifecycle and the pythons usually get the infection by preying on intermediate host such as frog, lizard, rodents and small warm blooded animals, which harbour the infective L₃ larval stages in their tissues (Taiwo *et al.* 2002). The ingested larvae undergo somatic migration before becoming adults. The nematodes described in the

python are strictly reptilian parasites. The animal might have got the infection through contact with other pythons (three in number) that were housed together or by contaminated feeding pots and bathing pools, or by eating infected rodents or chicken that are fed to them.

Conclusion: There was mild gastrointestinal parasite infection in the young captive python examined in Sri Venkateswara Zoo. The presence of no major lesions in the python suggests trifling infection at sub-clinical level. However, low grade infections should not be neglected. Presence of parasites, no history of deworming for the past few month accompanied by traumatic injury might have reduced the immune status of the animal. All the factors pooled together lead to chronic debilitation and death of the python.

References

- Ambrose, D. L., S. E. Little and K. S. Latimer (1999).** *Ophidascaris* in a reticulated python (*Python reticulatus*). <http://www.vet.uga.edu/vpp/archives/ivcvm/1999/ambrose/index.php#>
- Brar, R. S., P. P. Gupta and J. Misri (1990).** Observation on the post-mortem lesions in two pythons. *Indian Veterinary Journal* 67(6): 573.
- Burse, C. R and D. R. Brooks (2011).** Nematode parasites of Costa Rican snakes (Serpentes) with description of a new species of *Abbreviata* (Physalopteridae). *Comparative Parasitology* 78(2): 333-358.
- Meyer, N.C. and O.W. Olsen (1975).** *Essentials of Parasitology*. Second edition. C. Brown Corporation. Iowa. 303 pp.
- Panizzutti, M. H. M., L. C. dos Santos., J. J. Vincente., L. C. Muniz-Pereira and R. M. Pinto (2003).** *Ophidascaris durissus* sp. nov. (Nematoda Ascarididae) parasitizing *Crotalus durissus* Linnaeus (Ophidia, Viperidae) in Brazil. *Revista Brasileira de zoologia* 20(1): 9-11.
- Rao, A.T and Acharjyo, L.N (1984).** Diagnosis and classification of common diseases of captive animals at Nandankanan Zoo in Orissa (India). *Indian Journal of Animal Health*:147-157.
- Siqueira, L.R., M. H. M. Panizzutti., L. C. Muniz-Pereira and R. M. Pinto (2005).** Description of new ascaridoid parasite of *Bothrops jararaca* weid (Reptilia, Ophidia) in Brazil. *Revista Brasileira de zoologia* 22(3): 587-590.
- Taiwo, V. O., O. O. Alaka., N. A. Sadiq and J. O. Adejinmi (2002).** Ascaridosis in captive reticulated python (*Python reticulatus*). *African Journal of Biomedical Research* 5: 93-95.
- Taylor, M. A., R. L. Coop and R. L. Wall (2007).** *Veterinary Parasitology*. Third edition. Blackwell publications. London. 666-667pp.